

Xenomelia: a new right parietal lobe syndrome

Paul D McGeoch,¹ David Brang,¹ Tao Song,² Roland R Lee,² Mingxiong Huang,²
V S Ramachandran¹

► Additional materials are published online only. To view these files please visit the journal online (<http://jnnp.bmj.com>).

¹Center for Brain and Cognition, University of California, San Diego, La Jolla, California, USA

²Department of Radiology, University of California, San Diego, La Jolla, California, USA

Correspondence to

Dr Paul D McGeoch, Center for Brain and Cognition, University of California, San Diego, La Jolla, CA 92093, USA; pmcgeoch@mac.com

PDM and DB are joint status authors.

Received 16 April 2011
Accepted 22 May 2011
Published Online First
21 June 2011

ABSTRACT

Background Damage to the right parietal lobe has long been associated with various disorders of body image. The authors have recently suggested that an unusual behavioural condition in which otherwise rational individuals desire the amputation of a healthy limb might also arise from right parietal dysfunction.

Methods Four subjects who desired the amputation of healthy legs (two right, one left and one, at first, bilateral and then left only) were recruited and underwent magnetoencephalography (MEG) scans during tactile stimulation of sites above and below the desired amputation line. Regions of interest (ROIs) in each hemisphere (superior parietal lobule (SPL), inferior parietal lobule, S1, M1, insula, premotor cortex and precuneus) were defined using FreeSurfer software.

Results Analysis of average MEG activity across the 40–140 ms post-stimulation timeframe was carried out using an unpaired t test. This revealed significantly reduced activation only in the right SPL ROI for the subjects' affected legs when compared with both subjects' unaffected legs and that of controls.

Conclusions The right SPL is a cortical area that appears ideally placed to unify disparate sensory inputs to create a coherent sense of having a body. The authors propose that inadequate activation of the right SPL leads to the unnatural situation in which the sufferers can feel the limb in question being touched without it actually incorporating into their body image, with a resulting desire for amputation. The authors introduce the term 'xenomelia' as a more appropriate name than apotemnophilia or body integrity identity disorder, for what appears to be an unrecognised right parietal lobe syndrome.

INTRODUCTION

The mechanisms by which the brain constructs the sense of having a body—one's body image—are not completely understood. However, it has been known for some time through the study of patients with neurological lesions that damage to the right hemisphere, and particularly to the right parietal lobe, can lead to a variety of disorders of body image.^{1–9} These include left-sided neglect¹; an outright denial of paralysis named anosognosia by Babinski and a state of insouciance to paralysis, which he termed anosodiaphoria²; a hatred of the left side, labelled by Critchley as misoplegia^{3 4}; personification of a paralysed limb in which patients give it a specific name⁵ and supernumerary phantom limbs.¹ Additionally, Gerstmann described a peculiar delusion he called somatoparaphrenia, in which patients with right parietal lesions misattribute ownership of a paralysed left arm or leg to another person.⁶

We have recently suggested that there are certain parallels between somatoparaphrenia and an unusual behavioural condition in which otherwise rational individuals desire, and in many cases obtain, the amputation of a healthy limb.^{10 11} The previously postulated explanations as to why amputation of a healthy limb should be desired include that it is a sexual paraphilia, that it occurs to attract sympathy, that the sight of an amputee in infancy has been imprinted on the sufferer's 'psyche' and even that the supposed phallic resemblance of an amputee's stump is the underlying motivator.^{12–16} Conversely, in our experience, sufferers typically reported their main motivation being that the limb felt 'foreign', 'intrusive' or somehow 'overpresent', and our proposal that their desire might arise from right parietal dysfunction was drawn from three specific observations. First, somatoparaphrenia typically affects the left side of the body, and the desire for an amputation also shows a left-sided preponderance. Second, sufferers can often draw an exact line on the limb where they desire the amputation. Third, as with somatoparaphrenia, some individuals feel vaguely aversive to the limb in question.^{10 16}

Classically, disorders of body image have been associated with damage to the convexity of the right parietal lobe posterior to the post-central gyrus (S1).^{1 8} This area of the cortex is divided into the superior and inferior parietal lobules (the SPL and the IPL, respectively), with the latter being further subdivided into the supramarginal and angular gyri.^{1 17} It seemed to us that anatomically the right SPL was particularly well placed to combine disparate sensory inputs to construct a dynamic body image as it receives inputs from the dorsal visual stream, S1, S2, the premotor cortex and M1.^{17 18} Moreover, given that some patients who congenitally lack one or more limbs nonetheless describe phantom sensations, it may be that there is a hard-wired map of the body in the right SPL.^{19–21} Our specific prior hypothesis thus was that if this cortical representation in the right SPL failed to represent a particular limb, it might lead to the desire for amputation of this limb.

However, although this hypothesis would also be consistent with the evidence from brain-damaged patients that suggests bilateral representation of body parts occurs more in the right than in the left hemisphere,²² it is also germane to note that other brain areas than the right SPL, including some in the left hemisphere, have been implicated in the sense of body ownership.^{7 23–25} In particular, a functional imaging study using the rubber hand illusion (where a rubber hand being stroked synchronously with the subject's own obscured hand begins to be perceived as part of the body)

detected activation in the premotor cortex bilaterally, as well as in both posterior parietal regions.²⁵ Similarly, repetitive transcranial magnetic stimulation of not only the right but also separately the left IPL has been reported to attenuate the strength of the rubber hand illusion,^{26 27} and several studies have found that damage to the right supramarginal gyrus is associated with disorders of body image, including neglect and somatoparaphrenia.^{7 24 28} There is also evidence from functional imaging and from patients with disorders of body image that the insular cortex and the right insula in particular may play a role in the sense of body ownership.^{7 23 29}

In this paper, we present evidence that we interpret as supporting our prior hypothesis that the desire for an amputation in these individuals does arise from a distortion of their body image as represented in the right SPL. As well as serving to illuminate the neural mechanisms underlying the genesis of body image in the normal human brain, this finding also constitutes a previously unrecognised right parietal lobe syndrome. We go on to propose that as such the desire for an amputation, which has variously been termed apotemnophilia, amputee identity disorder and body integrity identity disorder,^{12 15 16 30} would be better henceforth termed 'xenomelia', from Greek words for 'foreign' and 'limb' (see online supplementary material A for a fuller account).

SUBJECTS, MATERIALS AND METHODS

Subject group

After permission from the UCSD Institutional Review Board, four subjects who desired lower limb amputations, but had not yet obtained them, were recruited via advertising to online support groups.³¹ In all cases, the subjects' psychiatric mental state examinations were normal and, unless otherwise indicated, so were their neurological examinations. All four subjects were men, heterosexual and able to indicate exactly by means of drawing a line where they desired amputations. Table 1 details their ages, desired amputation sites and whether they went on to obtain an amputation.

Subject 1

Subject 1 was a 29-year-old right-handed man who desired a right mid-tibial amputation. He recalled that a 'strong desire' for the amputation of his right leg around the middle of his tibia started around the age of 12 years and had been constant since then. He denied a sexual motivation, but stated that rather the presence of his right leg made him feel 'over-complete' and that he simply wanted it 'gone'. He had cut off the distal phalanx of his right middle finger after reading on the internet that this might alleviate his desire for amputation of his leg. He had no a priori desire to amputate this phalanx and its removal did not have an impact on the strength of his desire for his leg to be

amputated. He readily acknowledged that his feelings about his leg were not normal. On neurological examination, he reported that pinprick was, possibly, slightly duller in a stocking distribution from the mid-level of his right tibia down. He also commented that at other times the same area felt 'more sensitive' than the other side. A month after visiting us, he irrevocably damaged his right leg with dry ice, thus necessitating a right below-knee amputation.

Subject 2

Subject 2 was a 63-year-old right-handed man who reported that since the age of 4 years he had desired bilateral lower limb amputations. Specifically, he indicated that he wanted his right leg to be amputated four inches below his hip joint and his left leg to be amputated two inches below the knee, and he stated that these parts felt as if they were 'just not' his. He attributed his feelings about his legs to 'a possessive mother', 'an abusive boss' and a desire to 'fit in'. He noted that recently the left-side desire had become particularly strong, while conversely his desire for a right-sided amputation had decreased. He contacted us a year later to report that the desire for an amputation on his right side had almost completely disappeared. Several months after this, he had an elective left below-knee amputation and subsequently stated that he no longer had any desire for a right leg amputation.

Subject 3

Subject 3 was a 73-year-old left-handed man who reported that he had desired an amputation at the level of his left mid-thigh since the age of 6 years. He described the main issue being that his left leg felt somehow 'foreign'. He also remarked on a degree of sexual attraction towards lower limb amputees and at the thought of himself as an amputee. He stated that once, while cutting wood with a chainsaw, he had been on the verge of turning the saw on his left leg but that he had restrained himself. He also said that, because of his religious beliefs, he was determined to live the rest of his life with both legs, although he thought of being an amputee 'every day' and frequently pretended to be one.

Subject 4

Subject 4 was a 70-year-old ambidextrous man who reported that he had had the desire to be an amputee of some sort since the age of 4 years when he saw another boy whose hand had been amputated. He reported that since then he had been fascinated by amputees and recalled that when he was 12 years old he thought about crushing a leg under a bus, although he could not remember which leg. He also used to pretend to have only one arm when he was a teenager and also contemplated cutting off a finger. He denied any sexual attraction towards amputees. He first realised at the age of 65 years (via the internet) that there were other people with similar desires to his own. He reported that since then, his desire for an amputation had been focused on his right leg around the middle of his thigh. He reported that on three occasions he had attempted to gain an amputation; twice by means of a tourniquet that he aborted due to the pain and once he was on the verge of crushing the leg under his car but stopped at the final moment. He became adept at applying local anaesthetic nerve blocks and in early 2007 he carried out a right sciatic nerve block, which left him with a permanent palsy of his right common peroneal nerve. This was reflected in his neurological examination. As sensation over his medial calcaneum was normal, we chose this area (and the corresponding contralateral area) for stimulation

Table 1 Subject details

Subject	Age	Desired amputation sites	Proceeded to amputation
1	29	Right mid-tibial	Yes—R BKA
2	63	Left 2 inches below knee and right 4 inches below hip joint	Yes—L BKA
3	73	Left mid-thigh	No
4	70	Right mid-thigh	Yes—R AKA

AKA, above-knee amputation; BKA, below-knee amputation; L, left; R, right.

Research paper

during the magnetoencephalography (MEG) study. Over a year after visiting us, subject 4 had an elective right above-knee amputation.

MEG study of somatosensory responses

The MEG imaging in this study was conducted with UCSD's whole-head Elekta Neuromag 306-channel system in an enhanced multi-layer magnetically shielded room. The system records brain responses simultaneously from the entire scalp and samples the magnetic field with 510 separate pick-up loops configured into 204 gradiometers and 102 magnetometers. Four head position indicator coils were used for anatomical digitisation. The data sampling frequency was 1000 Hz. The data were run through a high-pass filter with a 0.1 Hz cut-off notch filter (58–62 Hz) to remove 60 Hz power-line noise.

Somatosensory evoked fields were recorded in the MEG scanner for each subject for six different conditions: tactile stimulation (tapping) of the dorsum of each foot (except for subject 4—see above), tapping of each anterior thigh about 5 cm below the inguinal crease (in all cases cleanly above any desired line of amputation) and electrical stimulation of the median nerve over the volar aspect of each wrist. The tapping was administered at approximately 2-second intervals using two fine fibre-optic filaments bundled together. A low-energy laser beam was emitted from one fibre-optic filament and the scattering of the laser light from the skin during contact with the filament allowed an optical switch to register each tap for the purposes of MEG trial averaging. In order to confirm that the intensity of somatosensory stimulation applied to each site was equivalent, the duration of diffracted light was analysed (see online supplementary material B). Median nerve stimulation was started at 6 mA and, if necessary, increased in 1 mA increments until perceptible movement of the thumb was observed.

In order to increase the signal-to-noise ratio, 100 artefact-free MEG responses were averaged with respect to each tapping stimulus triggered, and 200 artefact-free responses for each median nerve stimulation. This MEG protocol was then repeated on four controls, who were right-handed men aged 27, 48, 64 and 70 years. All the controls denied any desire for an amputation. After completion of the MEG study, all the participants underwent structural MRI brain scans, comprising T1- and T2-weighted imaging, gradient echo sequences, fluid attenuated inversion recovery and diffusion-weighted imaging.

The MEG trial-averaged datasets were analysed using the VESTAL solution for MEG³² (which is a MEG analysis technique that has been demonstrated to be capable of resolving neuronal sources that are spatially close together—see online supplementary material C) and integrated onto a FreeSurfer MRI reconstruction (see online supplementary material D).^{33–34} A non-parametric permutation analysis was used to verify these activation localisations (see online supplementary material E). The median nerve stimulations were additionally used to confirm accurate registration of the MEG data with the structural images obtained from FreeSurfer MRI reconstruction, since the areas of the cortex activated by median nerve stimulation are well recognised.

The 16 datasets generated by the tapping of each foot in the four subjects and four controls were visually inspected across the 40–140 ms post-stimulation time window by manually setting the relatively conservative threshold of activation to 0.04 nA/mm². The 40–140 ms time window was chosen in order to remove the contribution of sharp transient 20–30 ms components, which are mainly from thalamo-cortical projections. Moreover, the analysis of this time course was based on absolute

values of the source amplitudes, so there were no cancellations due to different polarities of the source time courses.

In order to best empirically assess the question of right SPL activation following each of the lower limb stimulations, a region of interest (ROI) was created for each subject and control, to coincide with the right SPL, as procedurally labelled during FreeSurfer reconstruction.³⁵ This ROI was then used to calculate the average evoked activity within the right SPL between 40 and 140 ms after each lower limb stimulation. Given the variety of brain areas that have been suggested to be involved in body representation, additional ROIs were procedurally labelled using FreeSurfer for the left SPL, right and left IPL, right and left insula, right and left M1, right and left S1, right and left premotor cortex and right and left precuneus (see online supplementary material F).

A traditional group analysis comparing legs with and without a desire for amputation was not possible, since subject 2 desired bilateral amputations and so did not have a healthy foot for comparison. To accommodate this fact, an unpaired *t* test (a relatively more conservative measure than the repeated measures ANOVA we would have used in a group analysis) was conducted comparing the ratio of foot/thigh activation in each particular ROI for each subject and control, as a function of whether or not amputation was desired (eight foot/thigh ratios from controls' legs and three foot/thigh ratios from subjects' unaffected legs, compared with the five foot/thigh ratios from subjects' affected legs).

RESULTS

The structural brain images were judged in all cases to be within normal limits. Visual inspection of the 16 foot stimulation datasets was carried out (see figure 1 and online supplementary material G). The unpaired *t* test of the right SPL ROI activity revealed significantly reduced activation in the legs that the subjects desired amputated relative to the subjects' unaffected legs and the controls' legs ($t(14)=3.336$, $p=0.005$) (see figure 2 and table 2). We also compared the subjects' affected legs solely with their own unaffected legs ($t(6)=2.39$, $p=0.05$) and separately with the controls' legs ($t(11)=3.42$, $p=0.006$), and found both of these differences also to be significant.

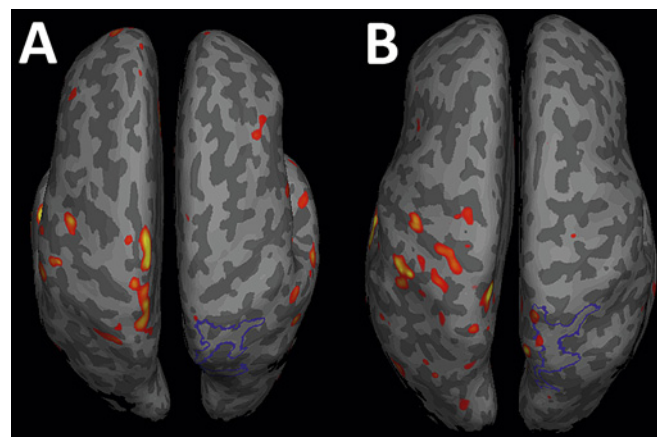
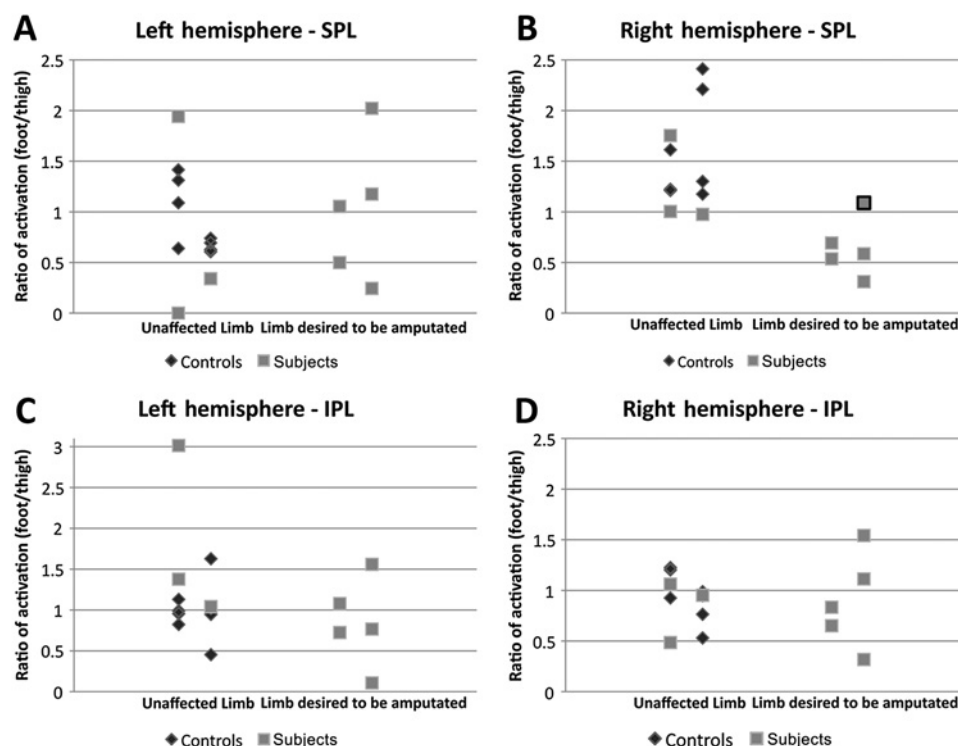


Figure 1 Average magnetoencephalography activation from 40 to 140 ms in response to a tactile stimulus applied to the right foot overlaid on the inflated left and right hemispheres of representative subject 4 (A) and a control (B) viewed dorsally. The right superior parietal lobule regions of interest are outlined in blue. The threshold is set from permutation testing with $p < 0.05$ (red) and $p < 0.00000001$ (yellow).

Figure 2 Ratios of magnetoencephalography activation (foot/thigh) for the left and right (A, B) superior parietal lobule (SPL) and (C, D) inferior parietal lobule (IPL) regions of interest (ROIs), as a function of whether or not amputation was desired. Data include eight foot/thigh ratios from controls' healthy legs and three foot/thigh ratios from subjects' unaffected legs, as well as five foot/thigh ratios from subjects' affected legs. Each column is subdivided into left and right limbs, respectively. In B (the right SPL ROI), one data point has a bold box surrounding it, to highlight the 'normal' ratio of activation in subject 2 for the right leg, which he desired amputated at the time of testing, but not at the 1-year follow-up.



In keeping with our prior hypothesis that the desire for an amputation is marked by dysfunction of the right SPL, the statistical analyses of each of the other 13 regions failed in every case to reach significance (see table 2). Specifically, analysis of the left and right IPL ROIs gave values of $t(14)=1.087$, $p=0.296$, and $t(14)=0.243$, $p=0.811$, respectively (see figure 2). As discussed, given that previous work has particularly implicated the right supramarginal gyrus in body image disorders, we split the right IPL into its two component gyri and analysed each individually, but again neither reached statistical significance; right supramarginal ROI $t(14)=1.21$, $p=0.248$, and right angular gyrus ROI $t(14)=0.78$, $p=0.450$. Finally, although as discussed, a group analysis comparing affected and unaffected legs was not possible, some degree of group comparison (using a repeated measures ANOVA with factors of group, laterality and stimulation site) was possible; this too supported a role for the right SPL ROI—see online supplementary material H.

DISCUSSION

The observation of a statistically significant reduction in MEG activity in the right SPL following tactile stimulation of the subjects' affected legs supports the hypothesis that the desire to amputate arises from a failure to adequately represent the affected limb in this area of cortex. Since the visual and somatosensory cortices are intact, the individuals with xenomelia can still see and feel the affected limb; however, if our hypothesis is correct and there is an insufficient corresponding representation of the affected limb in the right SPL, the unnatural consequence would be a conflict between these sensory inputs and a lack of adequate subsequent right SPL activity. In other words, sufferers would be able to see and feel a limb that nonetheless failed to incorporate into their body image.

This discrepancy may explain the significantly heightened change in skin conductance response (a marker of sympathetic activity)³⁶ to touch below the desired line of amputation, which we have previously reported in subjects 1 and 2.¹¹ Thus feeling

Table 2 Unpaired t test analyses comparing the ratio of foot/thigh activation in each region of interest (ROI) for subjects and controls, as a function of whether or not amputation was desired

ROI	Foot/thigh ratio of MEG activity			Healthy legs versus affected legs
	Controls' legs	Subjects' unaffected legs	Subjects' affected legs	
L SPL	0.89	0.76	1.00	$t(14)=0.453$ $p=0.657$
R SPL	1.52	1.24	0.64	$t(14)=3.336$ $p=0.005$
L IPL	0.99	1.81	0.85	$t(14)=1.087$ $p=0.296$
R IPL	0.97	0.83	0.89	$t(14)=0.243$ $p=0.811$
L insula	3.02	0.00	1.37	$t(14)=0.332$ $p=0.745$
R insula	0.49	0.11	0.13	$t(14)=0.605$ $p=0.555$
L M1	1.07	2.73	0.96	$t(14)=0.739$ $p=0.472$
R M1	1.06	0.79	0.99	$t(14)=0.015$ $p=0.988$
L precuneus	1.63	3.37	1.37	$t(14)=0.791$ $p=0.442$
R precuneus	0.58	1.28	0.77	$t(14)=0.010$ $p=0.992$
L premotor	1.42	5.21	0.55	$t(14)=1.552$ $p=0.143$
R premotor	1.17	0.19	1.89	$t(14)=0.876$ $p=0.396$
L S1	1.10	0.84	0.78	$t(14)=0.955$ $p=0.356$
R S1	1.08	1.17	0.61	$t(14)=1.743$ $p=0.103$

The only ROI to reach statistical significance was the right SPL, which is in bold. IPL, inferior parietal lobule; L, left; MEG, magnetoencephalography; R, right; SPL, superior parietal lobule.

the affected limb being touched in the absence of the normally associated right SPL activity may lead to a state of sympathetic arousal (possibly mediated by the right insula, an area known to be important in sympathetic control).³⁷ The consequence of

Research paper

such ongoing sympathetic activity could be to make the affected limb even more 'intrusive'. We have replicated this observation in subject 4, but subject 3 fell into the 10% of the population who do not manifest a change in skin conductance response to tactile stimuli (unpublished data). Interestingly, subject 3 was also the only subject who stated categorically that he would not seek an amputation, which raises the possibility that adrenoceptor antagonists might be effective in ameliorating the desire for an amputation.

As highlighted in figure 2, four out of five of the subjects' affected legs showed activation ratios well below that of any of the controls' or the subjects' unaffected legs. Intriguingly, the one leg showing relatively normal activity was the right leg of subject 2. As noted above, when we saw subject 2, he was in the process of losing his desire for a right-sided amputation; it is possible that the relative evoked activities in the right SPL seen here reflect this fact. Moreover, to the best of our knowledge, this is the first spontaneous loss of desire for an amputation to be reported. Although, at first sight, it would seem hard to incorporate this observation into the hypothesis that the desire for an amputation arises from right SPL dysfunction, this is not necessarily the case since, although cortical connections in the adult brain were once believed to be fixed and unmalleable, they are now known to possess a significant potential plasticity.¹⁹ It would thus be possible for subject 2's loss of desire to be explained on the basis of plastic changes in a nonetheless dysfunctional right SPL.

Given that the individuals concerned typically date their desire for an amputation to childhood,^{15 16} it could be that xenomelia arises from a congenital or early developmental dysfunction of the right parietal lobe, in contrast to such disorders as anosognosia and somatoparaphrenia, which arise from acquired damage. It is noteworthy that visual inspection of the MEG scans revealed ipsilateral S1/M1 activity to a certain extent in all the subjects but not the controls. It is not clear whether this unusual S1/M1 activity pattern occurred as a result of compensatory mechanisms for a deficit elsewhere (ie, in the right SPL) for example, via the recruitment of normally vestigial pathways, or because this area too is fundamentally dysfunctional. We also looked at the activity of the left SPL but did not observe any clear trends in either the subjects or the controls (see figure 2).

Importantly, these findings also serve to illuminate the mechanisms by which the brain represents the body and suggest an important role for the right SPL for bilateral limb representation. It is known that S1 receives input from large diameter myelinated A β fibres that convey the 'exteroceptive' senses of light touch, proprioception and vibration sense.^{38 39} Conversely, the dorsal posterior insula receives small diameter partially myelinated A δ fibres and unmyelinated C fibres carrying such 'interoceptive' senses as heat, cold, innocuous temperatures, mechanical stress, pH, hypoxia, lactic acid, hypoglycaemia and itch.^{38 39} It is thought that through subsequent remappings, these interoceptive inputs form a neural representation of affective state in the right anterior insula.^{38 39} Thus, if it is the case that the right SPL combines the exteroceptive senses that travel to S1 with visual input to form a representation of the body, the question of how this then binds with the interoceptive input to the insula remains to be addressed. Given its widespread cortical projections involving both interoceptive and exteroceptive cortical regions, including the fundus of the central sulcus and the parieto-insular cortex,⁴⁰ the solution may be found in the vestibular system.

Conditions such as xenomelia, which stand in the borderland between neurology and psychiatry, can deliver valuable insights into how neural activity generates mental phenomena. We believe that this work has broader implications than only being a new right parietal lobe syndrome or an explanation for a rare condition, as the findings also shed light on the neural underpinnings of body image in the normally functioning brain and show that a seemingly bizarre disorder, long discussed in psychodynamic terms, can in fact be explained in terms of specific dysfunction of known brain structures.

Acknowledgements We thank John R. Smythies, William H. Rosar, Elizabeth Seckel, Ashley Robb, Annemarie Angeles, Ron Eng, Emilie Yanagi and all the staff of Infusions of Tea.

Funding This work is partly funded by the Herb Lurie Foundation, which had no direct input into this study.

Competing interests None.

Ethics approval Ethics approval was provided by UCSD Institutional Review Board.

Contributors PDM: Developed theories, recruited subjects, established links with MEG Center, designed the study, examined and carried out experimental protocols and wrote the paper. DB: Handled the operation of MEG machine and data processing and wrote the paper, especially the more technical aspects and development of theories. TS: Gathered MEG data and trained DB on the finer points of MEG analysis. RRL: Interpreted MRI/MEG images. MH: Provided expert analysis of MEG data. VSR: Developed the theories, wrote the paper and examined the subjects.

Provenance and peer review Not commissioned; externally peer reviewed.

REFERENCES

1. **Critchley M.** *The Parietal Lobes*. London: Edward Arnold & Co., 1953:225–55.
2. **Babinski J.** 'Contribution to the study of mental disturbances in organic cerebral hemiplegia (anosognosia)'. *Rev Neurol* 1914;**22**:845–8.
3. **Critchley M.** Misoplegia, or hatred of hemiplegia. *Mt Sinai J Med* 1974;**41**:82–7.
4. **Loetscher T, Regard M, Brugger P.** Misoplegia: a review of the literature and a case without hemiplegia. *J Neurol Neurosurg Psychiatry* 2006;**77**:1099–100.
5. **Critchley M.** Personification of paralysed limbs in hemiplegics. *BMJ* 1955;**2**:284–6.
6. **Gerstmann J.** Problem of imperception of disease and of impaired body territories with organic lesions. *Arch Neurol Psychiatry* 1942;**48**:890–913.
7. **Vallar G, Ronchi R.** Somatoparaphrenia: a body delusion. A review of the neuropsychological literature. *Exp Brain Res* 2009;**192**:533–51.
8. **Roth M.** Disorders of the body image caused by lesions of the right parietal lobe. *Brain* 1949;**72**:89–111.
9. **Smythies JR.** The experience and description of the human body. *Brain* 1953;**76**:132–45.
10. **Ramachandran VS, McGeoch PD.** Can vestibular caloric stimulation be used to treat apotemnophilia? *Med Hypotheses* 2007;**69**:250–2.
11. **Brang D, McGeoch PD, Ramachandran VS.** Apotemnophilia: a neurological disorder. *Neuroreport* 2008;**19**:1305–6.
12. **Money J, Jobaris R, Furth G.** Apotemnophilia: two cases of self-demand amputation as a paraphilia. *J Sex Res* 1977;**13**:115–25.
13. **Bayne T, Levy N.** Amputees by choice: body integrity identity disorder and the ethics of amputation. *J Appl Philos* 2005;**22**:75–86.
14. **Wakefield PL, Frank A, Meyers RW.** The hobbyist. A euphemism for self-mutilation and fetishism. *Bull Menninger Clin* 1977;**41**:539–52.
15. **BIID Info.** http://biid-info.org/Main_Page (accessed 1 Jul 2010).
16. **First M.** Desire for an amputation of a limb: paraphilia, psychosis, or a new type of identity disorder. *Psychol Med* 2005;**35**:919–28.
17. **Hyvarinen J.** Posterior parietal lobe of the primate brain. *Physiol Rev* 1982;**62**:1060–129.
18. **Felleman DJ, Van Essen DC.** Distributed hierarchical processing in the primate cerebral cortex. *Cereb Cortex* 1991;**1**:1–47.
19. **Ramachandran VS, Hirstein W.** The perception of phantom limbs. The D. O. Hebb lecture. *Brain* 1998;**121**:1603–30.
20. **Brugger P, Kollias SS, Muerl RM, et al.** Beyond re-membering: phantom sensations of congenitally absent limbs. *Proc Natl Acad Sci U S A* 2000;**97**:6167–72.
21. **Hilti LM, Brugger P.** Incarnation and animation: physical versus representational deficits of body integrity. *Exp Brain Res* 2010;**204**:315–26.
22. **Sterzi R, Bottini G, Celani MG, et al.** Hemianopia, hemianaesthesia, and hemiplegia after right and left hemisphere damage. A hemispheric difference. *J Neurol Neurosurg Psychiatry* 1993;**56**:308–10.
23. **Tsakiris M.** My body in the brain: a neurocognitive model of body ownership. *Neuropsychologia* 2009;**48**:703–12.
24. **Feinberg TE, Venneri A, Simone AM, et al.** The neuroanatomy of asomatognosia and somatoparaphrenia. *J Neurol Neurosurg Psychiatry* 2010;**81**:276–81.

25. **Ehrsson HH**, Spence C, Passingham RE. That's my hand! Activity in premotor cortex reflects feeling of ownership of a limb. *Science* 2004;**305**:875–7.
26. **Tsakiris M**, Costantini M, Haggard P. The role of the right temporo-parietal junction in maintaining a coherent sense of one's body. *Neuropsychologia* 2008;**46**:3014–18.
27. **Kammers MP**, Verhagen L, Dijkerman HC, *et al*. Is this hand for real? Attenuation of the rubber hand illusion by transcranial magnetic stimulation over the inferior parietal lobule. *J Cogn Neurosci* 2009;**21**:1311–20.
28. **Vallar G**. Spatial frames of reference and somatosensory processing: a neuropsychological perspective. *Phil Trans R Soc Lond B* 1997;**352**:1401–9.
29. **Vallar G**, Ronchi R. Anosognosia for motor and sensory deficits after unilateral brain damage: a review. *Restor Neural Neurosci* 2006;**24**:247–57.
30. **Furth GM**, Smith R, Kuebler-Ross E. *Amputee Identity Disorder: Information, Questions, Answers, and Recommendations About Self-Demand Amputation*. Bloomington: Authorhouse, 2000.
31. **Support groups**. <http://health.groups.yahoo.com/group/fighting-it>; http://health.groups.yahoo.com/group/the_biid_affair/; <http://transabled.org>.
32. **Huang MX**, Dale AM, Song T, *et al*. Vector-based spatial-temporal minimum L1-norm solution for MEG. *Neuroimage* 2006;**31**:1025–37.
33. **Dale AM**, Fischl B, Sereno MI. Cortical surface-based analysis: segmentation and surface reconstruction. *Neuroimage* 1999;**9**:179–94.
34. **Fischl B**, van der Kouwe A, Destrieux C, *et al*. Automatically parcellating the human cerebral cortex. *Cereb Cortex* 2004;**14**:11–22.
35. **Fischl B**, Salat DH, Busa E, *et al*. Whole brain segmentation: automated labeling of neuroanatomical structures in the human brain. *Neuron* 2002;**33**:341–55.
36. **Critchley HD**. Electrodermal responses: what happens in the brain. *Neuroscientist* 2002;**8**:132–42.
37. **Craig AD**. Forebrain emotional asymmetry: a neuroanatomical basis? *Trends Cogn Sci* 2005;**9**:566–71.
38. **Craig AD**. Interoception and emotion: a neuroanatomical perspective. In: Lewis M, Haviland-Jones JM, Barrett LF, eds. *Handbook of Emotions*. 3rd edn. New York: Guilford Publications, 2008:272–88.
39. **Craig AD**. How do you feel—now? The anterior insula and human awareness. *Nat Rev Neurosci* 2009;**10**:59–70.
40. **Brandt T**, Dieterich M. The vestibular cortex. Its location, functions and disorders. *Ann N Y Acad Sci* 1999;**871**:293–312.

Information in a hurry...

If you need the latest information in emergency care then you need the **Emergency Medicine Journal**. Packed with research, educational papers and debate of all aspects of emergency medicine, the journal will make sure you know everything you need to.

FOR MORE DETAILS OR TO SUBSCRIBE,
VISIT THE WEBSITE TODAY

emj.bmj.com



BMJ Journals



Xenomelia: a new right parietal lobe syndrome

Paul D McGeoch, David Brang, Tao Song, et al.

J Neurol Neurosurg Psychiatry 2011 82: 1314-1319 originally published online June 21, 2011
doi: 10.1136/jnp-2011-300224

Updated information and services can be found at:
<http://jnp.bmj.com/content/82/12/1314.full.html>

These include:

References

This article cites 35 articles, 15 of which can be accessed free at:
<http://jnp.bmj.com/content/82/12/1314.full.html#ref-list-1>

Email alerting service

Receive free email alerts when new articles cite this article. Sign up in the box at the top right corner of the online article.

Notes

To request permissions go to:
<http://group.bmj.com/group/rights-licensing/permissions>

To order reprints go to:
<http://journals.bmj.com/cgi/reprintform>

To subscribe to BMJ go to:
<http://group.bmj.com/subscribe/>