

# Dynamic reorganization of referred sensations by movements of phantom limbs

Vilayanur S. Ramachandran, David Brang and Paul D. McGeoch

After amputation of an arm the sensory map of the body changes radically, causing the sensory input from face to 'invade' the original hand area in the brain. As a result, touching the face of the amputee evokes tactile sensations on the phantom. These sensory referrals from the face to phantom hand occur in a stable, topographically organized manner. We now find that volitional movements of the phantom cause striking, systematic shifts in the map along the direction of movement. We conclude that the reorganization of maps is based partly on reversible inhibition of ordinarily silent synapses, not entirely on new anatomical connections. This finding further highlights the dynamic nature of the brain on remarkably short-time

scales. *NeuroReport* 21:727–730 © 2010 Wolters Kluwer Health | Lippincott Williams & Wilkins.

*NeuroReport* 2010, 21:727–730

**Keywords:** amputee, homunculus, neural plasticity, phantom sensations, somatosensory

Center for Brain and Cognition, University of California San Diego, La Jolla, California, USA

Correspondence to Vilayanur S. Ramachandran, Center for Brain and Cognition, University of California San Diego, 9500 Gilman Dr 0109, La Jolla, CA 92093-0109, USA

Tel: +1 858 534 6240; fax: +1 858 534 7190; e-mail: vramacha@ucsd.edu

Received 16 April 2010 accepted 9 May 2010

## Introduction

Shortly after amputation, most individuals report continued sensory experiences in the missing limb [1,2]. In arm amputees, sensory stimuli applied to the ipsilateral face are felt as referred sensations to the missing (phantom) arm, often producing a topographically organized map of the hand on the face (Fig. 1a) with clearly delineated digits described as 'reference fields' (RFs) [3–5]. Accounting for these experiences, the right side of the body is mapped onto the postcentral gyrus of the left hemisphere; the map is systematically organized except for the face being directly below the hand rather than near the neck. After arm amputation, the sensory input from the face, which normally projects only to the face area, 'invades' the vacated territory corresponding to the denervated hand, similar to the reorganization of somatosensory maps in S1 shown in monkeys [6,7]. Accordingly, touch stimuli applied to the face now activate the hand region of the brain and are therefore interpreted by higher brain centers as arising from the phantom hand. A second map of referred sensations is often seen on the arm proximal to the amputation; this is caused by cross-activation of the hand area of the cortex by afferents from the upper arm, which normally projects only to the upper arm region of the cortex [4], a conjecture we confirmed using magnetoencephalography [8]. Interestingly, however, the cortical reorganization that occurs in upper limb amputees has been shown to reverse after transplantation as the hand allograft regains its sensorimotor representation [9,10].

The map of referred sensations is modality specific; warmth applied to the face elicits warmth in specific phantom digits and cold and vibration each elicit cold and vibration, suggesting that these sensations must be

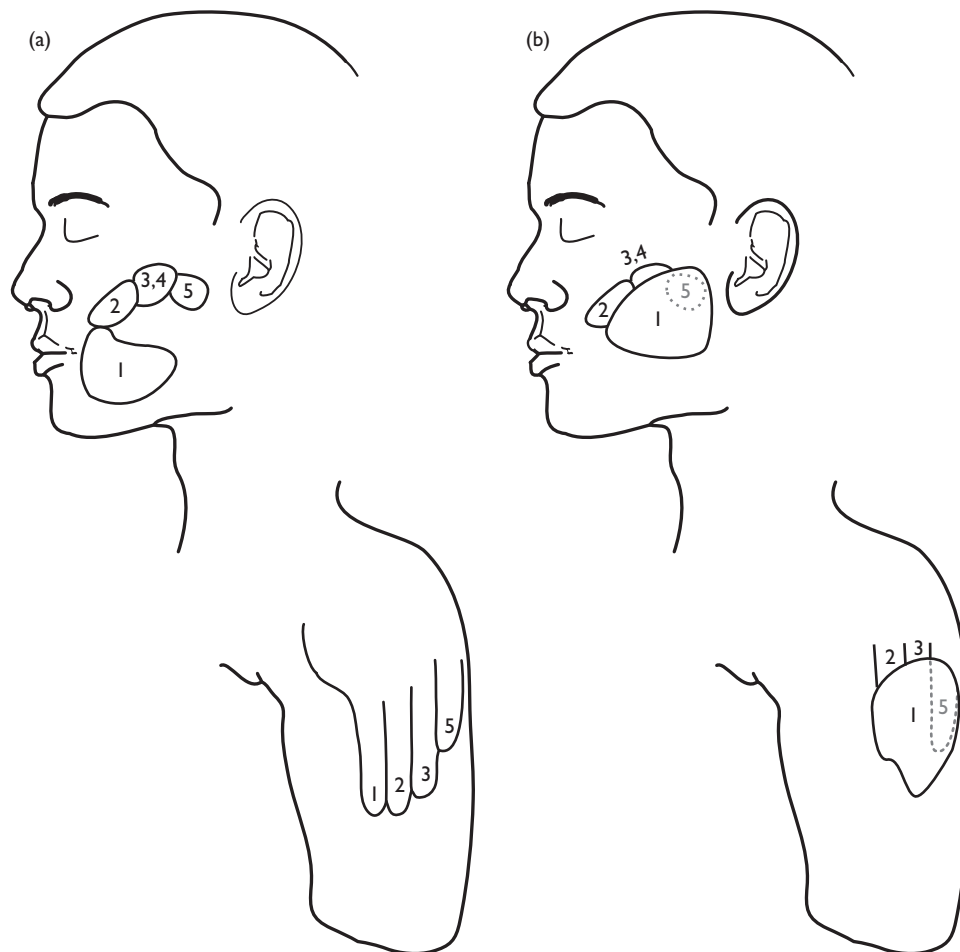
separately remapped in different brain regions. Furthermore, the observed topography of RFs on the face and arm remains remarkably stable over months or years [4]. Many amputees report the ability to volitionally 'move' the phantom, presumably through connections from the premotor and motor cortices to the superior parietal lobe [11], combining with visual, somatosensory, and proprioceptive inputs to create a representation of where the body is in space. However, in most cases there is a stable 'rest' position for the phantom; for example, it may be flexed, pronated, or supinated, unless the patient chooses to move his phantom temporarily. We wondered whether changes in RF topography would occur if the patient were to move his phantom to alter its posture from this resting position.

## Methods

D.S. (a 42-year-old male) had his left arm amputated 4 inches above the elbow at 19 years of age, following a brachial plexus avulsion 1 year before. He described a vivid phantom hand hanging from his stump and we found a distinct map on his ipsilateral lower face (Fig. 1a), with a second map on his distal stump. The rest position of D.S.'s phantom was full pronation. With effort he could oppose his phantom thumb over his fifth finger – accompanied by some supination – but other movements of his phantom were minimal; this was the only movement he could make.

During eight sessions spread over the course of a day we repeatedly mapped the RFs on D.S.'s face both to light touch (tip of a blunt pencil) and a cool stimulus (cotton bud dipped in ice water). D.S. was asked to shut his eyes and simply report whether there was sensation elsewhere

Fig. 1



Topographically organized map of sensations referred from the face and proximal upper arm to the phantom hand in the patient D.S. Numbers indicate digits. (a) Before movement of phantom. (b) After repositioning phantom.

(i.e. other than the face). Each session was carried out under two conditions: first, with D.S.'s phantom in the rest position; and second with D.S. actively holding his phantom thumb opposed against his fifth finger and the phantom hand partially supinated. The pencil tip was used to tap the same point on the skin three times (and stroke three times over excursions of about 4 mm). The sessions were videotaped for comparison purposes. After 2 months D.S. returned and the procedure was repeated with 10 sessions over a day.

## Results

In all 18 sessions in the rest position we found D.S.'s reports on the location of the referral to the phantom to be consistent and stable. The digits (except 3 and 4) were precisely defined and delineated from each other. When the mapping was repeated with a Q-tip dipped in iced water, the map of RFs for cold referral was precisely superposed on the touch map. However, in the active condition (supination of the phantom thumb), again in all

sessions, we found the map for light touch to be radically altered (Fig. 1b). Much to the patient's surprise – and ours – the thumb RF now shifted posteriorly along the face and 'spread' up to and past the pinky, so the latter became indistinct and much smaller (as if 'the thumb had occluded it' – to use his expression). The most striking demonstration of this was to tap his pinky representation when the hand was in the normal position and then asking him to oppose the thumb while we continued tapping. As soon as the opposition was complete he felt the thumb being tapped and the sensations on the pinky became weaker.

Conversely, when the cold stimulus was applied to the face in the active condition, the RF for the referral of cold sensation remained unchanged and clearly dissociated from the feeling of touch and pressure. In the case of applying cold stimulus to the RF reflecting the fifth digit before supination (and the thumb RF after supination), the touch was felt on the phantom thumb but the cold continued to be felt only on the phantom fifth digit.

**Table 1** Total number and type of stimuli applied across all sessions to each reference field (RF) located on the ipsilateral side of the face, as indicated in Fig. 1, the position of the phantom hand during each, and the phantom digit to which the stimulus was referred

Stimulus (position of phantom)	Reference fields (see Fig. 1)	Number of trials	Phantom digit to which stimuli referred (%)
Light touch (rest – Fig. 1a)	1	18	Thumb (100%)
	2	18	Index (100%)
	3,4	18	Middle/ring (100%)
	5	18	Little (100%)
Light touch (movement – Fig. 1b)	1	18	Thumb (100%)
	2	18	Index (100%)
	3,4	18	Middle/ring (100%)
	5	18	Thumb (100%) and little (indistinct – 100%)
Cool (both rest and movement – Fig. 1a)	1	36	Thumb (100%)
	2	36	Index (100%)
	3,4	36	Middle/ring (100%)
	5	36	Little (100%)

Thus, the thumb RF had expanded over a distance spanning 5 cm on the face but RF for cold remained unchanged, showing that the dynamic change in topography was limited to the touch domain (Table 1). As further confirmation of these findings, a  $2 \times 2$   $\chi^2$  analysis comparing RFs (thumb/pinky) to movement condition (rest/movement) yields a significant difference of reported locations to light touch ( $\chi^2 = 24.0$ , d.f. = 1,  $P < 0.01$ ), but there was no difference in the reported location in the cool stimulus condition ( $\chi^2 = 0.0$ , d.f. = 1,  $P = \text{NS}$ ).

The same experiment was then repeated on the second topographic map proximal to the stump with identical results (Fig. 1b). The thumb RF shifted and expanded several inches laterally, encroaching on and diminishing the pinky RF, and as before, ice and touch were dissociated. The RFs of digits 2, 3, and 4 also shifted laterally but became too indistinct to map out precisely.

Identical results were seen in a second patient FA, who was amputated below elbow at 35 years of age, 4 years before we saw him. With slight pronation of the phantom, the map for touch proximal to the elbow shifted medially and systematically by a finger's width but the map for temperature remained unaltered. The easiest way to show this was to place a small drop of ice water on the thumb RF before pronation. FA reported that upon pronation the drop of water 'jumped' to the phantom index finger, but the cold remained confined to the phantom thumb (FA was unavailable for testing in a second session).

## Discussion

These findings suggest that RFs are dynamic – not static. The brain may have a primordial (partly hardwired) habitual body image representation that resembles Da Vinci's famous engraving. This 'default' image – slightly different in each person – is likely constructed in the right superior parietal lobule using a combination of inputs from primary and secondary somatosensory cortices (S1/S2), proprioception, vision, and refference. Our results suggest that in addition to long-term changes in topography [6,7] there can also be acute short-term minute-to-minute updating based on corollary discharges from motor (and premotor) commands sent to the phantom

hand, as volitional movements of the phantom cause striking, systematic shifts in the map along the direction of movement.

The general idea of plasticity is also consistent with earlier experiments [4] showing that visual feedback – using optical means – can instantly modulate phantom pain. We had phantom patients look into a parasagittally positioned mirror, at the reflection of their normal hand optically superposed on the felt location of their phantom. If the patient moves his normal arm, the phantom not only appears to move but often also feels like it is moving, frequently relieving phantom pain [4]. Equally strong results have now been obtained using visual feedback in reflex sympathetic dystrophy [12,13].

Although the general idea of plasticity of cortical topography is now widely accepted, the case reported here is the first demonstration of rapid large-scale changes. We suggest that the reorganization of RFs to light touch described above is based partly on reversible inhibition of ordinarily silent synapses, not on new anatomical connections. Thus indicating that, contrary to being static, brain maps are dynamic on remarkably short-time scales. The finding potentially has far-reaching implications for understanding brain function and neuroplasticity.

## Conclusion

The map of sensory referrals for light touch from the face to a phantom hand can be systematically and reproducibly altered by a patient volitionally moving his phantom hand. Conversely, the map for referral of cool stimuli dissociates from the map for light touch and remains unchanged after the volitional movement of the phantom.

## Acknowledgements

The authors thank Abe Pollin, Herb Lurie and Dick Geckler for support.

## References

- 1 Sunderland S. *Nerves and nerve injury*. Edinburgh: Churchill Livingstone; 1972.
- 2 Riddoch G. Phantom limb and body shape. *Brain* 1941; **64**:197–222.

- 3 Ramachandran VS, Rogers-Ramachandran D, Anstis SM. Perceptual correlates of massive cortical reorganization. *Science* 1992; **258**:1159–1160.
- 4 Ramachandran VS, Hirstein W. Perception of phantom limbs. *Brain* 1998; **121**:1603–1630.
- 5 Halligan PW, Marshall JC, Wade DT, Davey J, Morrison D. Thumb in cheek? Sensory reorganization and perceptual plasticity after limb amputation. *Neuroreport* 1993; **4**:233–236.
- 6 Merzenich M, Kaas J. Reorganization of mammalian somatosensory cortex following peripheral nerve injury. *Trends Neurosci* 1980; **5**:434–436.
- 7 Pons TP, Garraghty PE, Ommaya AK, Kaas JH, Taub E, Mishkin M. Massive cortical reorganization after sensory deafferentation in adult macaques. *Science* 1991; **252**:1857–1860.
- 8 Yang TT, Gallen C, Schwartz B, Bloom FE, Ramachandran VS, Cobb S. Sensory maps in the human brain. *Nature* 1994; **368**:592–593.
- 9 Farne A, Roy AC, Giraux P, Dubernaud JM, Sirigu A. Face or hand, not both: perceptual correlates of reafferentation in a former amputee. *Curr Biol* 2002; **12**:1342–1346.
- 10 Vargas CD, Aballea A, Rodrigues EC, Reilly KT, Mercier C, Petruzzo P, et al. Re-emergence of hand-muscle representations in human motor cortex after hand allograft. *Proc Natl Acad Sci* 2009; **106**:197–202.
- 11 Ehrsson HH, Spence C, Passingham RE. That's my hand! Activity in premotor cortex reflects feeling of ownership of a limb. *Science* 2004; **305**:875–877.
- 12 Cacchio A, De Blasis E, Necozone S. Mirror therapy for chronic complex regional pain syndrome type 1 and stroke. *N Engl J Med* 2009; **361**:634–636.
- 13 Ramachandran VS, Hirstein W. The perception of phantom limbs. The D. O. Hebb lecture. *Brain* 1998; **121**(Pt 9):1603–1630.